

Leishmanias of Neotropical Porcupines: *Leishmania hertigi deanei* nov. subsp.

R. Lainson (*)

J. J. Shaw (*)

Abstract

A leishmanial parasite was isolated from 11 of 18 porcupines from the general area of Ponta de Pedras, Island of Marajó, Pará State, north Brazil. Two of the infected animals were identified as *Coendou prehensilis* (Linnaeus), and the other 9 are considered as a hitherto undescribed species of *Coendou*. The organism is clearly related to *L. hertigi* Herrer, of the Panamanian porcupine *C. rothschildi* Thomas, but morphological, serological and biochemical differences necessitate taxonomic distinction. The Brazilian parasite is therefore named *Leishmania hertigi deanei* nov. subsp., in honour of Dr. Leonidas Deane who first recorded it in porcupines from Piauí, Brazil. Like *L. h. hertigi*, *L. h. deanei* produces no visible pathological effects in its natural host. Scanty amastigotes are scattered, often singly, throughout the skin and in the viscera; usually they can be detected only after the *in vitro* culture of tissues in blood-agar medium, in which *L. h. deanei* grows readily. Attempts to infect hamsters and a guinea-pig with amastigote and promastigote forms were unsuccessful. The sandfly vector of the parasite is unknown.

INTRODUCTION

Leishmania hertigi Herrer 1971 was first described in the Panamanian porcupine *Coendou rothschildi* Thomas: it appears to be specific for this animal, in which it causes no apparent pathological effects. Amastigotes are scattered, in small numbers, throughout the upper dermis but they evoke no host-cell reaction. Parasites were also found in the spleen and liver.

Although scanty amastigotes were seen in smears prepared from skinsnips, most infections were detected by the culture of skin or viscera in a slightly modified Senekji's blood-agar medium (McConnell, 1963). Intradermal inoculation of promastigotes from

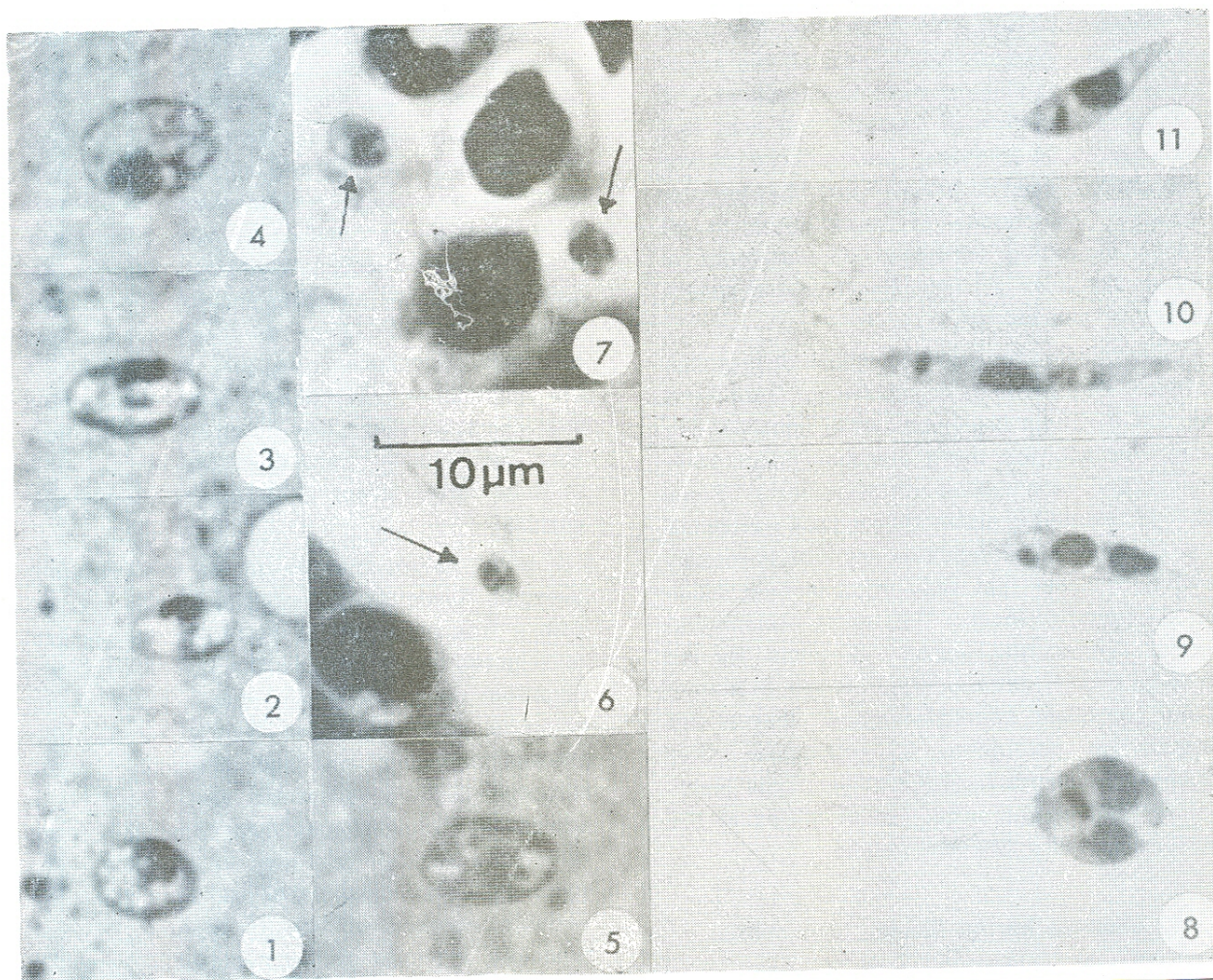
these cultures into hamsters produced relatively short-term infections in which small numbers of parasites could be seen in smears from the site of inoculation for only a few weeks. They could be demonstrated for longer periods by the culture of skin from the point of inoculation, on rare occasions up to one year later. No parasites were found elsewhere in the skin or viscera of the infected hamsters.

The incidence of infection in the Panamanian porcupines was very high, with 83 (88%) of 94 specimens positive. The infection was considered to be of long duration and confirmed to be up to 30 months in one captive animal.

Herrer gave a new specific name to the parasite, *Leishmania hertigi*, on the grounds of its apparent host-specificity in nature, failure of infection in hamsters to protect these animals against subsequent challenge with *L. braziliensis panamensis*, and the peculiar elongate nature of the amastigotes (Fig. 14). He measured and illustrated both promastigotes from culture, and amastigotes from smears of porcupine skin, but stressed only the importance of the latter in comparison with the morphology of other leishmanias. Biochemical studies on *L. hertigi* from Panama have confirmed its specific identity (Chance, *et al.*, 1974; Gardener, *et al.*, 1974). Lainson & Shaw (1973) provisionally placed the organism in the *L. braziliensis* complex but later (Lainson, *et al.*, 1977) removed it into a distinct group of its own, following observations on its behaviour in experimentally infected sandflies and its distinctive biological and biochemical characters.

Deane, *et al.*, (1974) examined spleen smears from a porcupine which was shot in the Mata do Cafundó forest, Município of José

(*) — Instituto Evandro Chagas da Fundação Serviços de Saúde Pública, Belém, Pará, Brazil.



Figs. 1-11. *Leishmania hertigi deanei* nov. subsp. 1-5, amastigotes in impression smears of liver and spleen of *Coendou* sp., from Pará State, north Brazil: Giemsa. 6-7, sections of skin from the tail of the same animal showing amastigotes scattered in the upper dermis: formol-saline fixation, haematoxylin & eosin. 8-11, cultural forms; showing rounded and elongate dividing stages, and long and short promastigotes.

mally and intraperitoneally into hamsters in attempts to infect them with the porcupine parasite; and other hamsters and a single guinea-pig were inoculated with rich suspensions of promastigotes.

RESULTS

Promastigote flagellates grew luxuriantly in cultures from 11 of the 18 porcupines, including both of the *C. prehensilis*. In 8 instances the parasite was isolated only from the skin; in 2 cases from the skin and viscera; and in 1, only from the viscera. Scanty amastigotes (Figs.

1-5, 13) were seen in the liver and spleen of one animal (*Coendou* nov. sp.): microscopic demonstration of amastigotes was otherwise limited to histological sections of the skin of the same animal (Figs. 6 & 7). These showed extremely scanty, single parasites scattered throughout the upper dermis and usually lying in a small vacuole. In section the amastigotes appeared much smaller than those in the liver and spleen smears (Figs. 1-7), doubtless due to shrinkage in the fixed tissue and/or expansion of the flattened parasites in impression smears. A similar size difference in sections and smears was noted for *L. hertigi* of the Panamanian porcupine (Herrer, 1971).

We were unable to determine the exact nature of the parasitized cell, for all the amastigotes seen in smears were extracellular and no clear association of parasite and host cell was apparent in sections. On no occasion was the organism seen to provoke any host cellular reaction. The paucity of amastigotes in all tissues examined permitted measurement of only 12 examples, all from the liver and spleen smears of one animal.

We have noted morphological differences between this parasite and *L. hertigi* from Panama, the Brazilian organism being considerably larger: in addition there are significant serological and biochemical differences⁽²⁾. Some form of taxonomic distinction is thus warranted and, as the two leishmanias are clearly closely related, we feel that separation is best made at subspecific level. The name *Leishmania hertigi deanei* nov. subsp., is given for the parasite from *C. prehensilis*, in Brazil, in honour of our old friend Leonidas Deane: that of the Panamanian porcupine, *C. rothschildi*, thus becomes *L. hertigi hertigi* Herrer. Type material is held in our collection of slides at the Institute Evandro Chagas, Belém.

***Leishmania hertigi deanei* nov. subsp.**

MORPHOLOGY OF THE AMASTIGOTE: (Figs. 1-5, 13).

The parasite is ellipsoidal and ranges from $5.1 \times 3.1 \mu\text{m}$ to $6.8 \times 4.5 \mu\text{m}$, average $6.1 \times 3.7 \mu\text{m}$. The cytoplasm stains a clear, bright blue and is markedly vacuolated. The nucleus is predominantly oval to round in outline: it measures approximately $2.5 \mu\text{m}$ in diameter and is usually placed close up against the cell wall. The kinetoplast is oval to rod-shaped, frequently curved: it is sometimes so close to the nucleus that it becomes difficult to detect.

MORPHOLOGY OF THE PROMASTIGOTE: (Figs. 8-12).

It is unfortunate that this description has to be based on promastigotes from *in vitro* culture, for in our experience with other

leishmanias the cultural forms may differ considerably from the various developmental stages seen in the sandfly vector.

The flagellates from 6-14 day-old cultures showed such a diversity of form that it is doubtful if average measurements of even a very large number would be very meaningful in a comparison with *L. h. hertigi*: the fact that both rounded and elongate division forms were equally common also complicates the description. Measurements and disposition of the nucleus and kinetoplast are fairly stable characters, however, and illustrations and mensural data (Table I) are therefore given for 20 cultural forms, from a 10 day-old blood-agar culture.

Body length and width of the smallest elongate forms may be as little as $6.0 \times 2.0 \mu\text{m}$, with a free flagellum of $11-16 \mu\text{m}$: larger promastigotes reach up to $18.0 \times 2.5 \mu\text{m}$, with the flagellum up to $24.0 \mu\text{m}$ long. Most of the elongate parasites taper gently to a finely pointed posterior end and possess a more abruptly pointed anterior: this imparts a somewhat "cigar-shaped" appearance. More rarely the anterior end may be rounded. The cytoplasm stains delicately and may contain a variable number of heavily stained, reddish granules. Position of the nucleus is variable; sometimes central, but most usually slightly more towards the anterior end of the flagellate. It is most commonly ovoid or rounded, sometimes elongated and more irregular. The kinetoplast is conspicuous, oval to kidney-shaped, rarely rounded: it is situated about $1.5 - 3.0 \mu\text{m}$ from the anterior end. The free flagellum is extremely variable in length, but many variations may be due to breakage in making the preparations. Elongate and rounded division stages are equally common, and bizarre forms may sometimes be found with three flagella or four nuclei.

HOST: *Coendou prehensilis* (Linnaeus) and *Coendou* sp. (nov. sp., Handley, *et al.*, see previous footnote).

TYPE LOCALITY: Ponta de Pedras, Marajó Island, Pará, State, north Brazil.

(2) — Personal communication from Mr. S. L. Croft, Dr. M. L. Chance and Dr. L. F. Schnur, Liverpool School of Tropical Medicine.

SITE AND TYPE OF INFECTION: throughout upper dermis, liver and spleen. Infection inapparent, with numbers of parasites frequently so low that they can be detected only after the culture of tissues in blood-agar medium. No visible pathology: absence of any host-cell reaction associated with parasites, which are often limited to single amastigotes widely scattered in the tissue.

INFECTIVITY FOR LABORATORY ANIMALS: no detectable infections have yet been produced in hamsters or the guinea-pig.

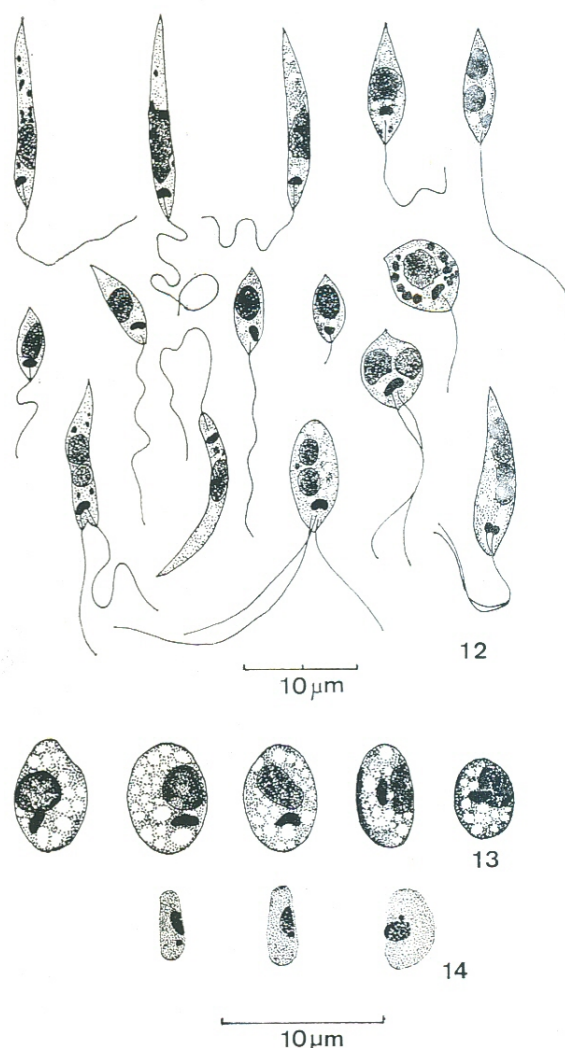
VECTOR: unknown. Presumably a phlebotomine sandfly.

TAXONOMY: Failure to establish either attached hindgut or foregut developmental stages in sandflies (Anon., 1967; Lainson, *et al.*, 1977) and characteristic biochemical features (Chance, *et al.*, 1974; Gardener, *et al.*, 1974) precludes the inclusion of *L. hertigi* in either the *L. braziliensis* or *L. mexicana* complexes: it was thus removed to a group on its own (Lainson, *et al.*, 1977). *L. hertigi hertigi* and *L. hertigi deanei* are differentiated by the morphology of the amastigotes, as seen in their respective porcupine hosts (present studies), serologically, and biochemically by electrophoretic mobility patterns of glucose phosphate isomerase and glucose-6-phosphate dehydrogenase (Croft, Schnur & Chance, personal communication).

DISCUSSION

The average measurements of the amastigotes described by Deane, *et al.*, (1974) in the porcupines from Piauí were $6.1 \times 3.4 \mu\text{m}$ — so similar to our own measurements of $6.1 \times 3.7 \mu\text{m}$ that there can be little doubt that these authors were also dealing with *L. h. deanei*. They described two other characteristics which agree with our own observations; namely the highly vacuolated nature of the cytoplasm, and the elongated form of the kinetoplast, which has the form of a small curved rod.

Leishmanias of Neotropical



Figs. 12-13. *Leishmania hertigi deanei* nov. subsp. 12, variety of dividing and non-dividing promastigotes seen in a 10-day-old blood-agar culture. 13, amastigotes in liver and spleen smears of *Coendou* sp. Giemsa. Fig. 14. *Leishmania hertigi hertigi*: amastigotes in skin smears of *Coendou rothschildi* (reproduced, at same scale, from Herrero, 1971). Note much smaller size, lack of vacuoles in cytoplasm, and different form of kinetoplast

Amastigotes of *L. h. deanei* would thus appear to be morphologically distinct from those of *L. h. hertigi*, in their respective porcupine hosts. The latter parasite measures only from 3.5 to $4.8 \mu\text{m} \times 1.2$ to $2.5 \mu\text{m}$ and the kinetoplast is "frequently rounded" (Herrero, 1971). Furthermore, Herrero's illustrations show no evidence of the prominent vacuolation so typical of *L. h. deanei*. The morphological

TABLE I. Measurements, in μ m, of 20 promastigotes of *Leishmania hertigi deanei* nov. subsp., from 10-day-old blood-agar cultures.

	Body Length	Body Width	K	Flgm	K — A	P — N	A — N	Diam Nucleus
1.	6.0	2.0	1.0 x 0.75	11.0	1.5	3.0	3.0	2.5 x 1.5
2.	6.5	2.0	1.0 x 0.5	16.0	1.75	3.0	3.5	2.5 x 1.5
3.	7.0	6.0	1.5 x 1.0	7.0	2.0	3.0	4.0	2.75 x 2.5
4.	7.5	2.5	1.0 x 0.5	17.5	2.0	3.5	4.0	2.5 x 2.0
5.	8.0	2.5	1.0 x 0.5	15.5	1.5	4.0	4.0	2.5 x 2.0
6.	8.5	2.5	1.0 x 0.5	15.0	2.0	4.0	4.5	2.5 x 2.5
7.	10.0	2.5	1.5 x 0.75	20.0	1.5	6.0	4.0	4.0 x 2.0
8.	10.5	3.0	1.0 x 0.5	12.5	3.0	4.5	6.0	3.0 x 3.0
9.	11.0	2.0	1.0 x 0.5	19.0	1.5	7.5	3.5	2.5 x 1.5
10.	12.0	1.5	1.0 x 0.75	13.0	2.5	7.0	5.0	3.0 x 1.5
11.	12.0	1.5	1.0 x 0.75	12.0	2.0	7.0	5.0	2.5 x 1.5
12.	12.0	2.0	1.0 x 0.5	19.0	2.0	6.5	5.5	5.0 x 2.0
13.	13.0	2.0	1.0 x 0.5	13.0	2.5	7.0	6.0	3.0 x 1.5
14.	13.0	2.0	0.75 x 0.5	15.0	1.5	8.5	4.5	3.0 x 1.75
15.	13.0	2.5	1.5 x 0.5	22.5	2.5	6.0	7.0	4.0 x 2.0
16.	14.0	2.0	1.0 x 0.75	10.0	3.5	8.0	6.0	3.0 x 2.0
17.	15.5	2.0	1.0 x 0.75	15.0	2.5	9.0	6.5	3.5 x 1.5
18.	17.0	1.5	1.0 x 0.75	19.0	2.0	11.0	6.0	4.0 x 1.5
19.	17.0	2.0	1.0 x 0.75	15.0	2.5	11.0	6.0	3.5 x 1.5
20.	18.0	2.0	1.25 x 0.5	24.0	2.5	11.0	7.0	6.5 x 1.5

K = kinetoplast; Flgm = flagellum; K — A = distance from kinetoplast to anterior end of body; P — N = distance from posterior end of body to middle of nucleus; K — A = distance from anterior end of body to middle of nucleus.

Lainson & Shaw

differences of the two parasites are shown in Figs. 13 & 14.

The vectors of both subspecies of *L. hertigi* remain unknown. Workers at the Gorgas Memorial Laboratory in Panama found *L. h. hertigi* to develop very poorly in the local sandfly species *Lutzomyia sanguinaria* and *Lu. gomezi* (Anon, 1967), and Lainson *et al.*, (1977) had no greater success with *L. h. deanei* in *Lu. longipalpis*.

ACKNOWLEDGEMENTS

These studies were carried out under the auspices of the Wellcome Trust, London, and the Instituto Evandro Chagas da Fundação Serviços de Saúde Pública, Belém, Pará, Brazil. We are particularly indebted to Roberto Daibes Naiff and Maricleide Dantas de Farias for their skilled technical assistance; to Mr S. L. Croft, Dr. M. L. Chance and Dr. L. F. Schnur of the Liverpool School of Tropical Medicine for making available to us their unpublished results of serological and biochemical studies on *L. h. hertigi* and *L. h. deanei*; and to Dr. C. O. Handley of the Smithsonian Institution, Washington, D. C., for identification of the porcupines studied in this work.

Sumário

Isolamento de *Leishmania* foi obtido de 11 em 18 porcos-espinhos da área geral de Ponta de Pedras, ilha do Marajó, Estado do Pará, Norte do Brasil. Dois dos animais infectados eram *Coendou prehensilis* (Linnaeus), e os outros 9 foram considerados como sendo uma espécie ainda não descrita de *Coendou*.

O parasita está claramente relacionado à *L. hertigi* Herrero, do porco-espinho do Panamá, *C. rothschildi* Thomas, porém existem diferenças morfológicas, sorológicas e bioquímicas, que tornam necessária a distinção taxonomica desse organismo. Desta maneira, o novo parasita encontrado no Brasil foi chamado *Leishmania hertigi deanei* nov. subsp., em homenagem ao Dr. Leonidas Deane, que foi o primeiro a registrá-lo em porco-espinhos do Estado do Piauí, Brasil.

Da mesma maneira que a *L. hertigi hertigi*, a *L. hertigi deanei* não produz efeitos patológicos visíveis em seu hospedeiro natural. Raros amastigotos, freqüentemente isolados, são encontrados na pele e nas vísceras. Usualmente são detectados apenas *in vitro*, por cultivo de tecidos em meio de agar-sangue, nos quais a *L. h. deanei* apresenta crescimento rápido.

Tentativas para infectar hamsters e cobaias com forma de amastigotos e de promastigotos não tiveram êxito.

O flebótomo vetor do parasita ainda é desconhecido.

LITERATURE CITED

- ANON.,
1967 — 38th Annual Report of the Work and Operations of the Gorgas Memorial Laboratory, Fiscal Year 1966. U.S. Govt., Printing Office, Washington.
- CHANCE, M.L.; PETERS, W. & SHCHORY, L.
1974 — Biochemical taxonomy of *Leishmania* I. Observations on DNA. *Ann. trop. Med. Parasitol.*, 68, 307-316.
- DEANE, L.M.; SILVA, J.E. & FIGUEIREDO, P.Z.
1974 — *Leishmaniae* in the viscera of porcupines from the State of Piauí, Brazil. *Rev. Inst. Med. trop. São Paulo*, 16, 68-69.
- GARDENER, P.J.; CHANCE, M.L. & PETERS, W.
1974 — Biochemical taxonomy of *Leishmania* II. Electrophoretic variation of malate dehydrogenase. *Ann. trop. Med. Parasitol.*, 68, 317-325.
- HERRER, A.
1971 — *Leishmania hertigi* sp. n. from the tropical porcupine, *Coendou rothschildi* Thomas. *J. Parasitol.*, 57, 626-629.
- HERRER, A.; THATCHER, V.E. & JOHNSON, C.
1966 — Natural infections of *Leishmania* and trypanosomes demonstrated by skin culture. *J. Parasitol.*, 52, 954-957.
- LAINSON, R. & SHAW, J.J.
1973 — *Leishmanias* and *leishmaniasis* of the New World, with particular reference to Brazil. *Bull. Pan. Amer. Hlth. Org.*, 7 (4), 1-19.
- LAINSON, R.; WARD, R.D. & SHAW, J.J.
1977 — *Leishmania* in phlebotomid sandflies. Importance of hindgut development in distinguishing parasites of the *L. mexicana* and *L. braziliensis* complexes. *Proc. Roy. Soc., (B)*, in press.
- MCCONNELL, E.
1963 — Leptomonads of wild-caught Panamanian *Phlebotomus*: culture and animal inoculation. *Exp. Parasitol.*, 14, 123-128.
- PINE, R.H.
1973 — Mammals (exclusive of bats) of Belém, Pará, Brazil. *Acta Amazonica*, 3(2): 47-79.
- SHAW, J.J. & LAINSON, R.
1976 — *Leishmaniasis* in Brazil: XI. Observations on the morphology of *Leishmania* of the *braziliensis* and *mexicana* complexes. *J. trop. Med. & Hyg.*, 79: 9-13.